

Congenital Diseases and a New York State Regulation

Help is Here

Preeti Gupta, D.D.S.; Stuart L. Segelnick, D.D.S., M.S.; Milton Palat, D.D.S., J.D.

Abstract

Knowledge of a little known New York State regulation and its insurance implications can be used to provide dental benefits to people who have congenital diseases or anomalies. An explanation of the regulation is provided, and some of the more common congenital diseases that may affect the dentition, such as amelogenesis imperfecta, dentinogenesis imperfecta, ectodermal dysplasia, cleft lip/palate and trisomy 21, are reviewed.

CONGENITAL DISEASES, though, fortunately, rare, do affect a number of people in New York State. The oral manifestation leaves a wide range of problems, such as missing teeth, malocclusion, elevated caries and periodontal disease, enamel and dental hypoplasia, cleft lips and palates, and facial deformities. These conditions present challenges for the people affected and their families. The assortment of difficulties faced by the afflicted cover the gamut of esthetic, functional and financial burdens.

The 2000 Surgeon General's Report on Oral Health in America states: "Over 108 million children and adults lack dental insurance, which is over 2.5 times the number who lack medical insurance."¹ With traditional dental insurance not covering a majority of procedures required to treat the oral component of these diseases, another means of alleviating the financial stress must be addressed.

Fortunately, New York State is on the frontier of this forward thinking and has a regulation aimed directly at this problem. The little-known regulation is found in the Official Compilation of Codes, Rules and Regulations of the State of New York.

The purpose of this article is twofold: first, to alert dentists who may be treating patients with congenital diseases or anomalies about a little-known New York State Insurance Department regulation that may help cover the cost of dental procedures in this population; and second, to review some of the more common congenital diseases that may affect the dentition.

The Regulation

In January 1999, Christopher, a 9-year-old living in a New York suburb, who was born with ectodermal dysplasia, was denied dental insurance coverage. Ectodermal dysplasia (ED) is a genetic disorder that negatively affects the victim's teeth, hair, nails and, often, ability to speak. Dental defects often include unpredictable patterns of tooth eruption and widely spaced teeth, poorly shaped teeth, cavity-prone teeth and, even, tooth agenesis.

Though New York State provides coverage for birth defects (of which ED is a recognized congenital defect), the insurance company denied dental coverage based on a conflicting State Insurance Department regulation. However, in December 1999, then Sen. Roy Goodman of Manhattan and then Chairman of the Senate Insurance Committee Guy Velella of the Bronx worked with the State Insurance Department to develop a new regulation that was especially helpful to Christopher and others affected by congenital

dental diseases.² That regulation is reprinted below.

NEW YORK STATE
INSURANCE DEPARTMENT
TWENTY-FIFTH AMENDMENT TO REGULATION 62
(11 NYCRR 52)
MINIMUM STANDARDS FOR THE FORM, CONTENT AND SALE
OF HEALTH INSURANCE, INCLUDING STANDARDS OF FULL
AND FAIR DISCLOSURE

I, Neil D. Levin, Superintendent of Insurance of the State of New York, pursuant to the authority granted by Sections 201, 301, 3201, 3216, 3217, 3221, 4235, and 4237 and Article 43 of the Insurance Law, do hereby promulgate the following Twenty-fifth amendment to Part 52 of Title 11 of the Official Compilation of Codes, Rules and Regulations of the State of New York (Regulation 62) to take effect upon publication in the State Register.

(MATERIAL UNDERLINED IS NEW; MATERIAL IN BRACKETS IS DELETED)

Subsection (9) of subdivision © of Section 52.16 of Part 52 of Title 11 of the Official Compilation of Codes, Rules and Regulations is hereby amended to read as follows: (9) dental care of treatment, except for such care or treatment due to accidental injury to sound natural teeth within 12 months of the accident [;] and except for dental care or treatment necessary due to congenital disease or anomaly;

I, Neil D. Levin, Superintendent of Insurance of the State of New York, do hereby certify that foregoing Twenty-fifth Amendment to 11 NYCRR 52 (Regulation 62) was duly promulgated by me on this day pursuant to the authority granted by Sections 201, 301, 3201, 3216, 3217, 3221, 4235, 4237 and Article 43 of the Insurance Law to take effect upon publication in the State Register.

Prior notice of this amendment was published in the State Register on July 21, 1999, as a Notice of Proposed Rule Making. No other publication or prior notice is required by statute.

Insurance

David Kupfer, M.D., who has held medical management positions at commercial and Medicaid HMOs and commercial carriers, has first-hand experience dealing with a patient with ED. Dr. Kupfer says he was oblivious to the law when the request was made for approval of procedures spanning several years and costing many thousands of dollars. The carrier's dental reviewer subsequently denied the request as cosmetic.

Upon appeal, the patient's parent, not the dentist, forwarded information about the newly enacted regulation (11 NYCRR Section 52.16 (c) (9), Regulation 62), mandating benefits for congenital conditions. After many phone calls and much research, the denial was overturned.

Dr. Kupfer says many insurers might still be unaware of the change in regulations. He advises dentists to first submit to the

patient's dental insurance if the patient is covered. The next step is to submit the explanation of benefits (EOB) denying the proposed treatment to the patient's medical insurance (see below recommendations when submitting to the medical carrier) as if it was a secondary dental carrier. Since the majority of people do not have dental insurance, most requests will be submitted directly to the medical insurance, which is where the regulation comes into effect. The provider should follow these recommendations when initially requesting approval from the medical carrier:

1. Submit a cover letter, very brief and to the point. Address it to the medical director by name. State that the patient has ED and that state regulations have been changed so that congenital conditions must now be covered by insurance. Also, state that the requested procedures are medically necessary and conform to best practices.
2. Make sure the carrier is aware of the change in regulations. Submit a copy of the changed regulation on New York State letterhead (available online).
3. Prove to the carrier that the patient has the condition. Submit documentation from a medical professional, that is, geneticist, verifying the patient's condition.
4. Demonstrate that the treatment plan is medically necessary. Besides X-rays, send in color pictures. Describe how difficult it is for the patient to eat, chew, talk, etc. Reinforce the treatment plan with documentation from the dental society and ED Society. Show that the plan follows "best practices." There is plenty of material online.³

According to Dr. Kupfer, providing as much information as possible up front to the carrier may prevent an initial denial. He further suggests that if the case is denied, follow the appeal procedures and follow up with a phone call to the medical director. There are usually three levels of appeal. If it is necessary to go further than level one, a well-worded letter from an attorney can work wonders.

Congenital Disease and Abnormalities

There are multiple common congenital defects with implications to clinical dentistry due to varying etiologies. The more common congenital defects with major pediatric dentistry implications discussed in this paper include amelogenesis imperfecta, dentinogenesis imperfecta, ectodermal dysplasia, cleft lip/palate and trisomy 21. We have provided other varied congenital defects with dental implications and treatment options (Tables 1 and 2), and have listed anomalies of the teeth (Table 3).

Amelogenesis Imperfecta

Amelogenesis imperfecta (AI) by definition is when teeth are characterized by thin malformed enamel. It is a Mendelian autosomal dominant, recessive or x-linked inherited trait with multiple hereditary defects. It exists independent of any related systemic disorders and is not related to other parts of the body. Incidence of AI varies from 1:700 to 1:15,000.⁴

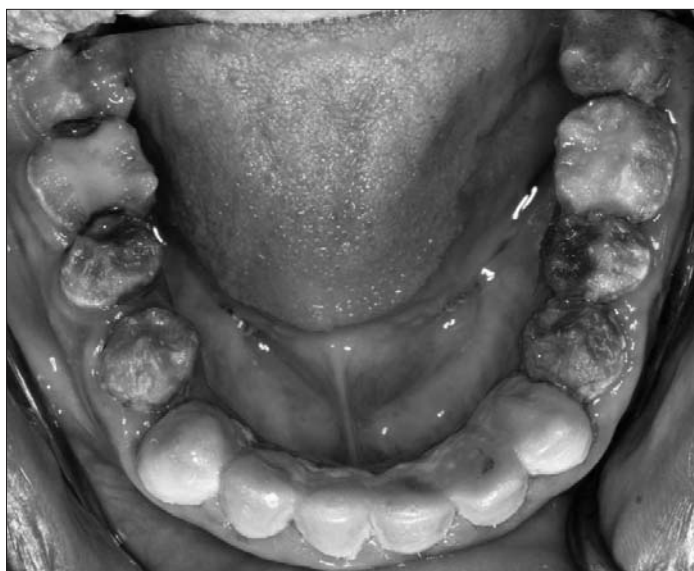TABLE 1Common Birth Defects. Etiology and Frequency¹⁴⁻²⁴

| Congenital Abnormalities and Syndromes | Etiology | Frequency |
|---|----------------------------------|---------------|
| Amelogenesis Imperfecta | Nutritional / Systemic disorders | 1/718 |
| Branchio-Oto-Renal Dysplasia (BOR)-EYA1 gene mutation | Single gene disorders | 1/40,000 |
| Cleft Lip / Palate | Multifactorial | 1/600-1/1,850 |
| Crouzon Syndrome | Inherited / Autosomal dominant | 1/25,000 |
| Down's Syndrome (Trisomy 21) | Chromosomal disorders | 1/800 |
| Dentinogenesis Imperfecta | Inherited / Systemic disorders | 1/8,000 |
| Edward's Syndrome (Trisomy 13) | Chromosomal disorders | 1/6,000 |
| Ectodermal Dysplasia | Inherited / X-linked recessive | 7/10,000 |
| Klinefelter's Syndrome (47, XXY) | Chromosomal disorders | 1/500 |
| Nevoid Basal Cell Carcinoma Syndrome-PTCH gene mutation | Single gene disorders | 1/57,000 |
| Patau Syndrome (Trisomy 18) | Chromosomal disorders | 1/10,000 |
| Smith-Lem Li Opitz Syndrome | Single gene disorders | 1/20,000 |
| Stickler Syndrome | Single gene disorders | 1/10,000 |
| Treacher-Collins Syndrome or Mandibulofacial Dysostosis | Single gene disorders | 1/50,000 |
| Turner's Syndrome (45, X) —females | Chromosomal disorders | 1/2,500 |
| Velocardiofacial Syndrome Chromosome 22 (22q11) | Chromosomal deletions | 1/4,000 |
| 47, XXX | Chromosomal disorders | 1/500 |
| 47, XYY | Chromosomal disorders | 1/500 |

- **Classification:** Classification of AI is based upon its variability and abnormalities in enamel. It is usually classified based upon clinical presentation of hypoplasia, hypomaturation or hypocalcification. Type I is hypoplastic AI; Type II is hypomaturation AI; Type III is hypocalcified AI; and Type IV is hypomaturation/hypoplasia/taurodontism. Further subclassification into distinct subtypes is performed based upon clinical appearance and mode of inheritance, for example, Type IV AI is exclusively autosomal dominant inheritance.

Clinical features of AI include teeth with varying colors, from white opaque to yellow to brown mottled (Figure 1). The crown size of teeth varies from normal appearance to microdontia. Teeth also lack proximal contacts because of abrasion and/or chipping of enamel. Radiological findings of AI typically include reduced bulk of enamel, with malformed intercuspation of teeth. The enamel contrast is either similar to or greater than dentin. Unerupted crowns have normal morphology. In Type IV AI, large pulp chambers are observed on radiographs.

- **Implications:** Clinically, patients with AI have teeth sensitivity to thermal, mechanical and/or chemical stimuli. Enamel is found to be brittle and can abrade easily. The teeth involved include the primary and secondary dentition. Hypomineralization of pits, grooves and fissures is usually present. Open bite and malocclusion may also be present. Masticatory function may be further diminished or severely compromised in some cases. Excess calculus and plaque formation secondary to rough enamel matrix is almost always present, leading to periodontal complications and caries.
- **Treatment:** Treatment for AI includes a multidisciplinary approach for management, involving the pediatric dentist/general dentist, prosthodontist, periodontist, orthodontist and oral

**Figure 1.** Amelogenesis Imperfecta

and maxillofacial surgeon. The pediatric dentist can preserve and maintain the primary dentition with stainless steel crowns. He or she can also preserve the mixed dentition with full coverage crowns to correct for enamel hypoplasia, which causes severe tooth sensitivity and lack of masticatory function. These patients will require continuous care; therefore, transitional restorations are placed, to maintain the dentition from childhood to adulthood. For example, pits, fissures and grooves can be restored with composite on teeth with minor AI. Minor enamel hypoplasia can be restored with flowable and filled resins, which reduce enamel sensitivity to decalcified areas. In cases of minor hypoplasia of anterior teeth, veneers can be fabricated.

TABLE 2**Birth Defects and Recommended Treatments¹⁴⁻²⁴**

| Congenital Conditions | Other Features | Major Recommended Dental Treatment |
|---|--|---|
| Albright Osteodystrophy | Delayed eruption, fibrous dysplasia lesions | Orthodontic rehabilitation |
| Amelogenesis Imperfecta | Enamel pitting/hypoplasia, brown-orange/white discoloration | Dental prosthetic rehabilitation |
| Branchio-Oto-Renal Dysplasia | Cleft fistulae, high-arched palate, cleft palate, bifid uvula | Reposition arch relationship with orthodontic and orthognathic treatment |
| Caffey's Disorder | Hypocalcemia, hypophosphatemia (absence of parathyroid tissue) | Oral hygiene, periodontal therapy |
| Cherubism-Abnormal Sh3BP2 gene | Hamartomas, displaced follicles, delayed eruption, expansion post. mand. | Orthodontic and oral surgery |
| Cleidocranial Dysplasia/Dysostosis | Delayed eruption, max. hypoplasia, supernumerary teeth, cementum dysplasia | Reposition arch relationship with orthodontic and orthognathic treatment |
| Crouzon's Disease | Craniostylosis, ocular hyperterorism, maxillary hypoplasia, proptosis, teeth may be missing, peg shaped, or enlarged | Craniomaxillofacial surgery, consider prosthetic rehab, orthodontics, and dental implants |
| Dentinogenesis Imperfecta | Periapical infection, missing pulp, dentin malformations, discolorations | Dental prosthetic rehabilitation |
| Down's Syndrome (Trisomy 21) | Delayed eruption, flat midface | Reposition arch relationship with orthodontic and orthognathic treatment |
| Ectodermal Dysplasia | Hypotrichosis, hypohidrosis, hypodontia, delayed eruption | Oral hygiene, restorative, orthodontics, prosthodontics, possible dental implants |
| Edward's Syndrome (Trisomy 13) | Orofacial cleft | Reposition arch relationship with orthodontic and orthognathic treatment |
| Hemifacial Microsomia | Mandibular hypoplasia, maxillary hypoplasia, macrostomia | Reposition arch relationship with orthodontic and orthognathic treatment |
| Histocytosis X | Prepubertal periodontitis, possible bony lesions | Oral hygiene, periodontal therapy |
| Hypophosphatasia | Prepubertal periodontitis, cementum dysplasia, early loss primary teeth | Oral hygiene, periodontal therapy |
| Hypopituitarism | Delayed eruption | Orthodontic rehabilitation |
| Hypothyroidism | Delayed eruption | Orthodontic rehabilitation |
| Incontinentia Pigmenti | Delayed eruption | Orthodontic rehabilitation |
| Leukocyte Adhesion or Migration Defects | Prepubertal periodontitis | Oral hygiene, periodontal therapy |
| Neonatal Hyperbilirubenemia | Discoloration of teeth, blue to black | Dental prosthetic rehabilitation |
| Neutropenia | Prepubertal periodontitis | Oral hygiene, periodontal therapy |
| Nevoid Basal Cell Carcinoma Syndrome | Multiple OKC's, cleft lip/palate, prognathism mand. | Oral surgery, dental rehabilitation |
| Papillon-Lefèvre Syndrome | Prepubertal periodontitis, premature loss of teeth | Oral hygiene, periodontal therapy |
| Pierre Robin Sequence | Micrognathia, cleft palate | Reposition arch relationship with orthodontic and orthognathic treatment |
| Ricket's | Delayed eruption (hypophosphatemia) | Orthodontic rehabilitation |
| Smith-Lem Li Opitz Syndrome | Cleft palate, microcephaly, micrognathia | Reposition arch relationship with orthodontic and orthognathic treatment |
| Stickler Syndrome | Cleft palate, micrognathia, midfacial hypoplasia | Reposition arch relationship with orthodontic and orthognathic treatment |
| Tetracycline Staining | Discoloration of teeth | Dental prosthetic rehabilitation |
| Treacher-Collins Syndrome | Hypoplasia, agenesis, enamel opacity, cleft lip/palate, mand./max. hypoplasia | Reposition arch relationship with orthodontic and orthognathic treatment/dental rehab |
| Turner's Syndrome (45, X) —females | High in-utero mortality | |
| Velocardiofacial Syndrome Chromosome 22 -22q11 | Cleft palate, retrognathia | Reposition arch relationship with orthodontic and orthognathic treatment |

TABLE 3**Teeth Anomalies and Their Effect²⁵**

| Anomalies (Abnormalities) of Teeth | Effect |
|------------------------------------|---|
| Microdontia | Abnormally small teeth |
| Macrodontia | Abnormally large teeth |
| Gemination | Single tooth with two crowns but one pulp chamber and root |
| Fusion | Dental union of two developing teeth, with two separate pulp canals, fused or separate canals may appear as large bifid crown |
| Concrescence | Fusion that occurs after root formation is complete |
| Dilaceration | Abnormal bend in the root of a tooth |
| Dens Invaginatus | Invagination of inner enamel epithelium (tooth within a tooth) |
| Dens Evaginatus | Evagination of enamel epithelium, focal hyperplasia of pulp mesenchyme |
| Taurodontism | Enlarged crowns, large pulps |
| Supernumerary Roots | Alteration in shape |
| Enamel Pearls | Alteration in shape |
| Anodontia | Absence of teeth |
| Supernumerary Teeth | Alteration in number |
| Amelogenesis Imperfecta | Defects in enamel |
| Dentinogenesis Imperfecta | Defects in dentin |
| Dentin Dysplasia | Defects in dentin |
| Regional Odontodysplasia | Defects in enamel and dentin |
| Endogenous Stain | Alteration in color |

Correction of severe dental and skeletal malocclusions (e.g., skeletal open bite deformity in AI) is managed by both orthodontists and oral surgeons. Orthodontists perform closure of interdental spaces. Oral and maxillofacial surgeons correct any open bite deformity resulting from severe erosion of enamel surgically. Skeletal correction procedures and dental implants may be necessary when teeth are removed. Complete dental rehabilitation via use of crowns and/or implants may be performed by prosthodontists. It is not uncommon to see delayed or partial eruption of permanent premolars and molars, which will need to be corrected by gingival surgery to expose the crown and then uprighted via orthodontics.

Dentinogenesis Imperfecta

The teeth of people afflicted with dentinogenesis imperfecta (DI) are characterized by abnormal dentin formation. It is genetically linked to osteogenesis imperfecta (OI) or may occur solely in teeth. Its overall prevalence is approximately 1:8000.⁵

- **Classification:** Classification of DI is based upon its association with OI (Type I).⁵ Type I is attributed to numerous mutations in pro- α chains of Type I collagen in OI. Type II is the most common and is known as hereditary opalescent dentin.⁵ Type II is attributed to genetic autosomal dominant mutation in the DSPP (dentin sialophosphoprotein) gene, which encodes DSPP (dentin sialoprotein) and DPP (phosphoprotein). Type III (brandywine type—isolate opalescent dentin) is an autosomal dominant mutation and has the clinical shape of shell-like teeth, due to their enlarged pulp chambers.⁵

Types I and II are clinically and radiographically similar in features. These features involve variable pulp obliteration, abnormal

crown or root morphology, blue-gray to yellow-brown discoloration and fractured enamel. They affect primary and permanent dentition equally.⁵

- **Implications:** All DI results in loss of enamel on primary and permanent teeth and some to the gingival margin, resulting in closed bite deformity. Histologically, dentin is relatively normal, but scalloping at the DEJ is missing, which results in the lack of mechanical enamel support.
- **Treatment:** Treatment varies according to the severity of each case and has to be determined upon assessment of individual teeth. In the primary dentition, stainless steel crowns are indicated when wear is apparent on the primary molars. Pulp therapy is usually required where obliteration of root canals has occurred. And in some cases, teeth have to be extracted. In the pediatric population, crowns can be undertaken to restore the form and function of anterior teeth if sufficient remaining tooth support is present. This is usually required if the family is concerned about aesthetics. In the permanent dentition, most teeth will require either partial or complete crown coverage. Bleaching can be considered prior to the final restoration of choice.

Restorative rehabilitation involves treatment, such as crowns and root canal therapy, on involved teeth to protect dentin from caries, attrition and/or erosion. Complete prosthodontic rehabilitation may involve restoration of closed bite by opening the bite, and this may involve dental restorations/prosthesis with or without implants as the loss of teeth occurs. These procedures involve multiple specialty coordination, including prosthodontists, general practitioners, endodontists, periodontists and the pediatric dentist.

Ectodermal Dysplasia

Ectodermal dysplasia (ED) encompasses a large and diverse group of diseases of ectodermal tissue origin. These may affect hair, nails, teeth, sweat glands, and minor salivary and lacrimal glands. Its prevalence is 7:10,000 births.⁶ It can be X-linked dominant, recessive, or the result of sporadic mutation of multiple genes. The pathogenesis is the result of altered epithelial-mesenchymal interaction involved in intracellular communication and signaling, cell development, survival or differentiation.

- **Classification:** ED is classified into two distinct groups. Group A includes at least two classic (i.e., hair, nail, teeth and sweat gland) structures with or without other defects. Group B involves one classic and at least another ectodermal defect.⁶
- **Implications:** Typical clinical facial features involve frontal bossing, prominent supraorbital ridges, anti-mongoloid palpebral slant, prominent ears, short and wide nose, concave profile and deep labio-mental folds. Intraoral findings include prevalence of natal teeth, multiple missing primary and permanent teeth. Other features include hypotrichosis, hyperkeratotic or dry skin, hypohydrosis, hypodontia and microdontia.⁶
- **Treatment:** Treatment for ED includes a multidisciplinary approach for management⁶ involving a pediatric or general dentist, orthodontist, periodontist and oral and maxillofacial surgeon. Orthodontists and oral surgeons manage correction of facial and skeletal deformity. The skeletal deformities are cor-

rected with staged facial skeletal osteotomies, orthognathic surgeries and/or distraction osteogenesis. Complete dental rehabilitation via use of crowns and/or implants may be required by prosthodontists for hypodontia and microdontia. The pediatric dentist can preserve and maintain carious primary dentition with stainless steel crown restorations and maintain esthetics through occlusal restorations, build-ups, indirect/direct onlays, strip crowns and porcelain veneers as indicated. This also restores vertical dimension of teeth and face. The partial edentulism can also be treated temporarily with removable prosthesis (pedi-partial) and, subsequently, permanently with endosseous dental implants. In children, current literature supports placement of endosseous implants in the anterior mandible.⁷ This requires adjustments of abutments with growth and can provide a good alternative for children with anodontia of mandible by having a fixed, detachable, complete mandibular denture.

Although this genetic disorder is considered relatively rare, appropriate interventions, instituted at an early age, will help maintain a healthy oral cavity and allow patients to develop socially, physically and emotionally.⁸

Cleft Lip/Palate

Cleft lip/palate is the most common of the craniofacial anomalies, with an incidence of 1/600-1/1850.¹ Cleft lip occurs when there is a lack of fusion of the medial nasal process with the maxillary

process. Cleft palate is the failure of fusion of the palatal shelves. When cleft lip and palate exist independently without other malformations, it is considered nonsyndromic in nature.

Classification: Cleft lip and palate vary in their clinical presentations. Veau proposed the most frequently used classification system.⁹ He classified clefts of the lip as follows: Class I – unilateral notching of the vermilion, not extending into the lip; Class II – a unilateral notching of the vermilion border, with the cleft extending into the lip but not including the floor of the nose; Class III – unilateral notching of the vermilion border of the lip with the cleft extending into the floor of nose; Class IV—any bilateral clefting of the lip, whether incomplete notching or complete notching. Veau also divided the palatal clefts into four classes: Class I involves only the soft palate; Class II involves the soft palate and hard plate but not the alveolar processes; Class III involves the soft and hard palates and the alveolar processes on one side of the premaxilla area; Class IV involves both the soft and hard palates and continues through the alveolus on both sides of the pre maxilla, leaving it free and mobile.


- **Implications:** Patients born with cleft lip/palate have many problems that have to be addressed by a specialized team that comprises a variety of health care professionals. The cleft palate team is made up of dental/medical and allied health care specialists. The pediatric dentist needs to address common dental anomalies, such as natal, neonatal teeth, congeni-

tally absent teeth, supernumerary teeth and ectopic primary lateral incisors, which can be associated with clefting individually or simultaneously. Other various anomalies, such as enamel hypoplasia, microdontia, macrodontia, fused teeth, and alterations in crown shape, can also occur.¹⁰

Permanent teeth can also be affected by clefting. The canines are usually erupting palatally into the cleft; teeth that erupt adjacent to the cleft can be deficient in alveolar bone support and are usually seen in a more rotated position. This can be corrected surgically by secondary bone grafting. Occlusion is usually altered due to existing crossbites, open bites, and discrepancies in the growth of the maxilla and mandible. Therefore, optimum dental care is needed and emphasized for total rehabilitation of these patients.

A recent cross-sectional study in the *Journal of Periodontology* (2007) showed that there is a high prevalence of gingival recession in individuals with cleft lip/palate with increasing age (which is similar to people without clefts). However, teeth adjacent to clefts were 10-times more likely to have gingival recession than people without clefts. Therefore, these patients should be treatment planned and evaluated by a periodontist for possible periodontal plastic procedures.¹¹

- **Treatment:** The treatment of cleft lip and palates is done in stages, which should be determined by the team. Because of the multifaceted problems that occur, broad spectrums of experts have to play a key role in the treatment planning.



Team members include an orthodontist, a prosthodontist, speech pathologists, social workers, medical geneticists, oral maxillofacial surgeon and/or a plastic surgeon. The surgeon usually determines the timing and method of lip closure, bone grafting, pharyngoplasty and correction of the cleft nasal deformities.

Trisomy 21

Trisomy 21 (Down's syndrome) is the most common of all trisomy syndromes.¹² It has a prevalence of 1:800 live births, and increases as maternal age increases. Most individuals with Down's syndrome have three copies of the entire chromosome 21 (90%), while 10% have trisomy (three copies) of a part of the long arm of chromosome 21.¹²

- **Classification:** No further classifications exist. Etiology and pathogenesis are unknown, possibly altered segregation in meiosis.
- **Implications:** Clinical features involve brachycephaly, small ears, upslanted palpebral fissures (mongloid slant), flat mid face and hypotonia. Trisomy 21 is usually associated with congenital heart malformations such as ventricular septal defects (40%), mental retardation (100%) and atlantoaxial subluxations (15%).¹² Intraoral evaluations typically discover dental hypoplasia and delayed eruption.

The presence of intellectual impairment and longer life span (40-50 years) necessitates dental rehabilitation and preventive dentistry. Many patients have good tolerance for the dental exam and treatment, but most require general anesthesia for complete dental rehabilitation.¹³

- **Treatment:** Treatment for Down's syndrome includes a multidisciplinary approach to comprehensive management with the pediatric dentist and/or general dentist, orthodontist and oral and maxillofacial surgeon. Orthodontists and oral surgeons manage correction of facial and skeletal deformities. The pediatric dentist can preserve and maintain the primary dentition with stainless steel crown restorations, dental extractions, restorations (composite and amalgam), and dental prophylaxis as indicated. Oral hygiene instructions and maintenance of the permanent dentition, coupled with regular dental appointments, including instructions to the patient's caregiver, are important parts of their treatment plan.

Conclusion

In each case, treatment for AI, DI, ED, cleft lip/palate and trisomy 21 includes multidisciplinary approaches. This review should not be considered all-inclusive in terms of treatment planning. Dentistry is both an art and science, and the final treatment plan will be up to the health care professionals and the needs of the patient. The skills, education, training and experience of the individual dentists will ultimately determine who treats these patients.

We have outlined (Tables 1 and 2) other frequent birth defects, their etiology, and common oral and maxillofacial implications. Most birth defects, as outlined above, involve multiple coordination

of dental specialties with the general and pediatric dentist.

Knowledge of the New York State regulation and its insurance implications may be used to provide benefits to people who have congenital diseases or anomalies and are very much in need of dental treatment. ■

Queries about this article can be addressed to Stuart Segelnick at EperioDr@aol.com

The authors wish to thank Dr. David Kupfer for his insight and invaluable assistance in preparing this paper; Dr. Leonard Gallo, Brookdale Hospital Director Pediatric Dentistry, for his editorial assistance; and a special thanks to Dr. Edgar Fayans, Brookdale Hospital Chairman Department of Dentistry and Oral Surgery.

REFERENCES

1. U.S. Department of Health and Human Services. Oral Health in America: A Report of the Surgeon General. Rockville, MD: U.S. Department of Health and Human Services, National Institute of Dental and Craniofacial Research, National Institutes of Health, 2000.
2. Governor's Office of Regulatory Reform. Available at http://www.govr.state.ny.us/success_labor.html Accessed February 2, 2007.
3. National Foundation for Ectodermal Dysplasia. Available at <http://www.nfed.org/Insurance.htm> Accessed November 13, 2006.
4. UNC Dentistry. Development Defects of Teeth: Amelogenesis Imperfecta, Dentinogenesis Imperfecta. UNC Dentistry online 1-25. Available at <http://www.dent.unc.edu/research/defects/index.cfm> Accessed July 5, 2006.
5. Knezevic A, Tarle Z, Panduric V. Esthetic reconstruction of teeth in patient with dentinogenesis imperfecta—a case report. *Coll Antropol* 2006;30(1):231-4.z
6. Ryan ES. Ectodermal dysplasia—as unusual dental presentation. *J Clinical Pediatric Dent* 30(1):55-58, 2005.
7. Kearns G. Implants in Children. In: Piecuch, JE. OMS Knowledge Update, Vol. 3. Rosemont, IL: AAOMS;2001. p. PED 67-81.
8. Gruber J, Kreitzberg G. Ectodermal dysplasia. A seven-year case report. *N Y State Dent J* 2006;72(6):28-31.
9. Veau V. Treatment of the unilateral hairlip. *International Dental Congress, Eighth Transaction* 1931; p126-131.
10. McDonald R, Avery D, et. al. *Dentistry for the Child and Adolescent*. 8th Ed. St. Louis: Mosby; 2004 p686-710.
11. Almeida AL, Madeira LC, Freitas KC, Greggi SL, Pegoraro LF. Cross-sectional evaluation of the presence of gingival recession in individuals with cleft lip and palate. *J Periodontol* 2007;78(1):29-36.
12. Carey J. Chromosome Disorders. In: Rudolph A, et. al. *Rudolph's Pediatrics* 21st Ed. New York: McGraw Hill; 2002. p.1-14.
13. Boyd D. The Down syndrome patient in the dental practice. *New Zealand Dental Journal* 2004 Mar;100(1): 4-9.
14. Spraycar M. *Stedman's Medical Dictionary*. 26th Ed. Philadelphia: Williams & Wilkins; 1995.
15. Beers M, Berkow R, et. al. *Dental and Oral Disorders, Teeth & Peridontium*. In: Beers M, et. al. *Merck Manual*. 17th Ed. Philadelphia: Merck & Co; 1999. p.103-108.
16. Steiner R. Smith Lemli Opitz Syndrome: eMedicine 2005: p1-20. <http://www.emedicine.com/ped/topic2117.htm> Accessed July 16, 2006.
17. Jahrsdoerfer RA. Treacher Collins Syndrome: otologic and auditory management. *J Am Acad Audiol* 1195 Jan; 6(1): 93-102.
18. Printzlau A, Pierre Robin sequence in Denmark: a retrospective population-based epidemiological study. *Cleft Palate Craniofacial J*. 2004 Jan; 41 (1): 47-52.
19. Tinanoff N. The Oral Cavity. In: Behrman R, Robert M, editors. *Nelson Textbook of Pediatrics*. 17th Ed. Philadelphia: Saunders; 2004. p. 1204-16.
20. Stoler J. Molecular Genetics and Syndrome Recognition for the Clinician. In: Kaban L, Troulis M, editors. *Pediatric Oral and Maxillofacial Surgery*. Philadelphia: Saunders; 2004. p. 20-36.
21. Eversole L. Benign Tumors of the Oral Cavity. In: Greenberg M, Glick M, editors. *Burkett's Oral Medicine Diagnosis and Treatment*. 10th Ed. Hamilton: BC Decker Inc; 2003. p. 1-63.
22. Sundell S. Hereditary Amelogenesis Imperfecta: an epidemiological, genetic, and clinical study in a Swedish child population. *Swed Dental J (suppl)* 1986;151-226.
23. Paller A. Selected Genetic Disorders of the Skin. In: Rudolph A, et. al. *Rudolph's Pediatrics*. 21st Ed. New York: McGraw Hill; 2003. p. 1-14.
24. Neville B, Damm D, et. al. *Oral & Maxillofacial Pathology*. Philadelphia: Saunders; 1995. p36-37.
25. Regezi J, Sciubba J. Abnormalities of Teeth. *Oral pathology: Clinical Pathologic Correlations*. 3rd Ed. Philadelphia: W.B. Saunders Company; 1999. p. 453-78.